

Concept and clinical case

A new immediate loading concept using a multitrough implant and a transepithelial abutment

EDUARDO ANITUA, DDS, MD, PHD^{1,2}, VITORIA, SPAIN

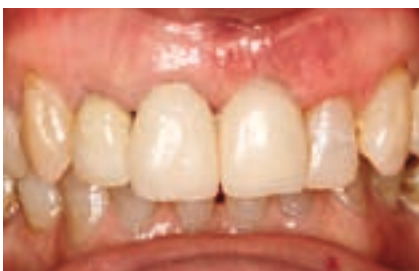Immediate loading has become almost routine in oral implantology, reducing the time needed to provide an implant-supported rehabilitation and improving aesthetics and function [1,2]. While immediate-loading protocols are well established and professionals who adopt them are quite familiar with them, establishing a proper seal and a passive fit for immediately loaded single crowns continues to be a major challenge [3–5].

To resolve this problem, post abutments have been used as mesostructures for provisional crowns – generally cemented ones – to achieve the desired seal and fit at the level of the implant/restoration interface. The seal established for the post abutment at the gingival level sometimes has to be broken when taking impressions for the definitive prosthesis. In addition, the manipulation of the soft

tissue 24 to 48 hours after surgery for the insertion of the micro-milled or cast post abutment means that this option is not ideal in many cases.

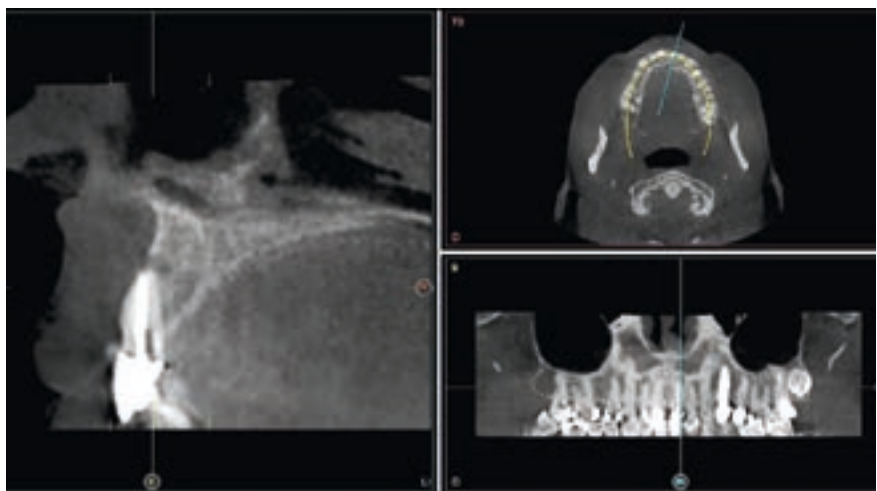
A systematic review with a meta-analysis of the immediate-loading protocol depending on the type of restoration did not find any statistically significant differences between the various types of prosthesis used (stationary,

removable, provisional and definitive). However, there were greater increases in ISQ values in the follow-up of immediate-loading patients when the prostheses were definitive, which appears to indicate that not removing the prosthesis improves not only the seal and behaviour of the soft tissue but also the integration of the immediately loaded implant [6].



1 | Initial intraoral image of the patient. Inflammation at the gingival level at tooth 21 and a probing depth of 12 mm.

2 | The CT scan also shows a complete loss of the vestibular plate and an active granuloma in the apical area of tooth 21, consistent with a diagnosis of vertical fracture.



¹ Private practice in oral implantology, Eduardo Anitua Clinic, Vitoria, Spain

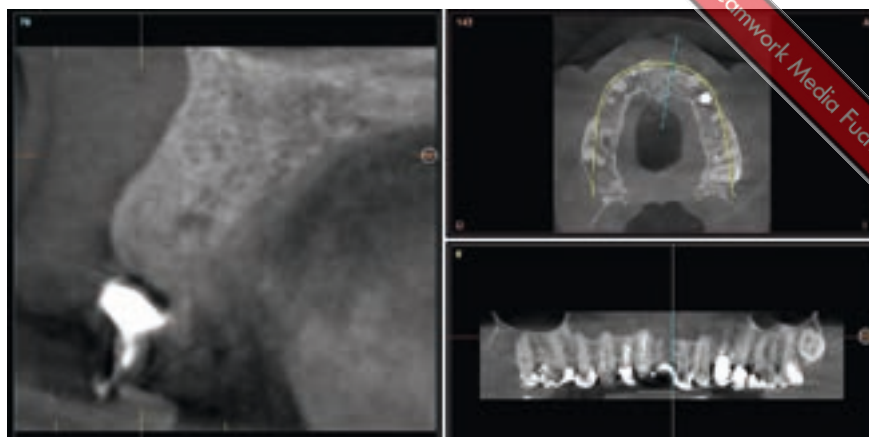
² Clinical researcher, Eduardo Anitua Foundation, Vitoria, Spain

This review raises the question whether, in addition to the presence of a provisional or definitive prosthesis affecting the integration of the immediately loaded implant, a specific design of the implant and prosthesis based on different surfaces adapted to the various tissues with which they interact could improve the success rate of our immediate-loading protocol. This concept, called BioBlock (different surfaces adapted to different tissues; BTI Biotechnology Institute, Vitoria-Gasteiz, Spain), was crucial to success in our recent investigations, as it increased the predictability of our implant treatments, including those with immediate loading.

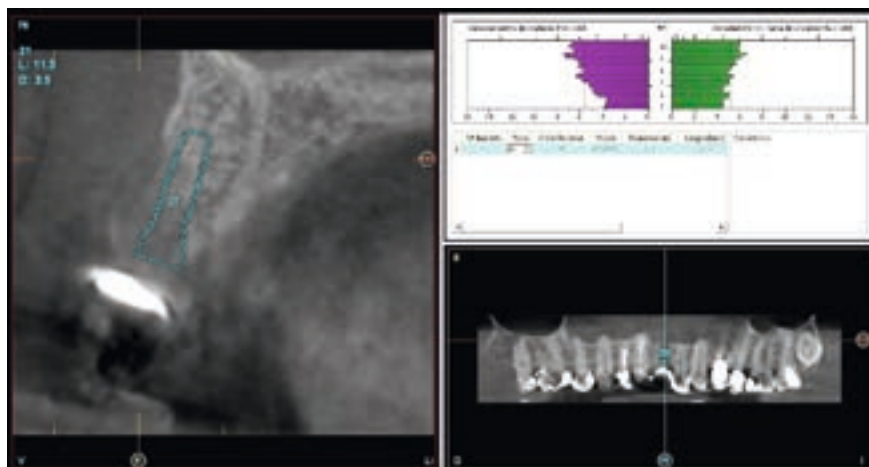
The Unit abutment (BTI Biotechnology Institute, Vitoria-Gasteiz, Spain) was conceived to meet these key issues, as well as others related to a good seal and passive fit of single-tooth restorations. It consists of an antirotational transepithelial post for screw-retained single-crown cases that achieves passive fit and a tight seal in a definitive restoration right from the start of the surgery, simplifying the manufacture of the immediately loaded prosthesis. In addition, this abutment is part of the BioBlock concept mentioned above, connecting the adapted surface (UnicCa with multirough surfaces: reduced roughness at the neck to aid bone stability and minimize bacterial colonization, moderate roughness with pores on the thread to improve the stability of the implant, and moderate roughness on the body to aid osseointegration without risking the mechanical properties of the implant) and a Ti Golden surface while maintaining the passive fit and tight seal at the implant/restorative interface that ensures the correct behaviour of the assembly and improves the success rate.

Clinical case

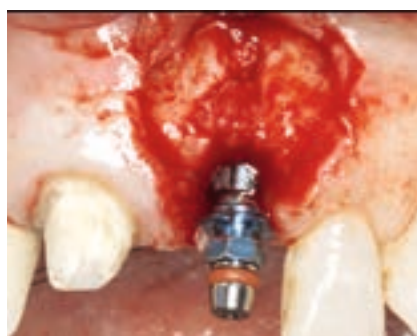A 63-year-old patient presented with a vertical fracture of tooth 21 with complete loss of the vestibular plate and related symptoms (Figs. 1 and 2). The tooth was extracted and the socket regenerated with PRGF-Endoret (BTI Biotechnology Institute, Vitoria-Gasteiz, Spain). A provisional was cemented onto the adjacent teeth that had been prepared



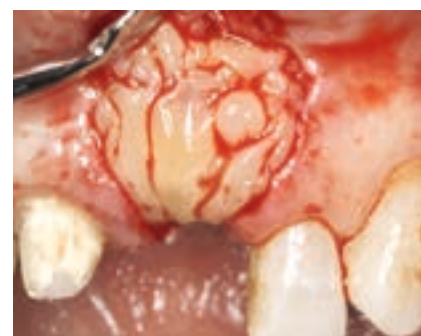3 | Bone status in the post-extraction socket area regenerated with PRGF-Endoret after twelve weeks.



4 | Planning for implant 21.



5 | Insertion of implant 21. Vestibular placement of a small amount of a particulate bone graft obtained from drilling together with PRGF-Endoret activated fraction 2.



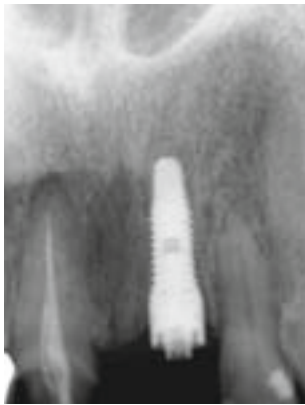6 | Membrane of PRGF-Endoret activated and retracted fraction 1 completely covering the surgical site.

for later restoration together with the implant to be inserted at site 21.

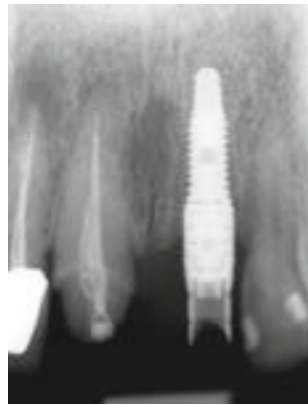The CT scan at twelve weeks post-extraction showed complete regeneration of the defect, allowing implantological planning to proceed (Figs. 3 and 4).

The implant bed was prepared using a low-speed drilling protocol and the

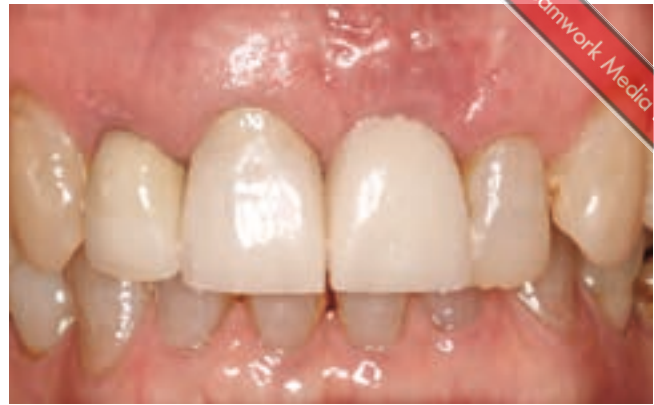implant inserted. The resulting bone chips were mixed with PRGF-Endoret and used as particulate bone graft in the vestibular area to fill a slight dehiscence that had formed due to uneven healing of the vestibular plate (Figs. 5 and 6). The site was covered with a fibrin membrane (PRGF-Endoret, fraction 1 activated and



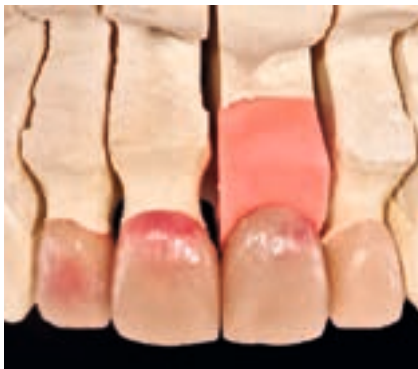7 | Radiograph of the provisional seated on the Unit abutment interface.



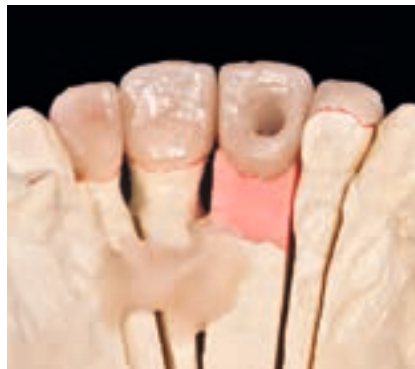8 | Soft tissue on suture removal at two weeks.



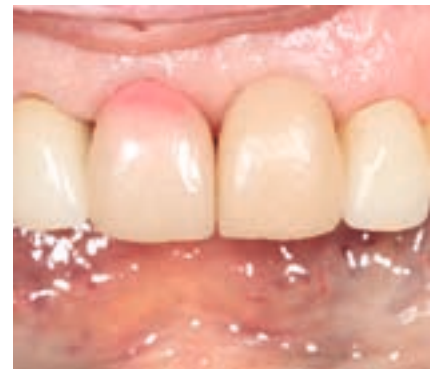9 | Diagnostic wax-up levelling the gingival margins.



10 | Details of the planned restorations: ceramic crowns on 11 and 12, a new screw-retained crown on Unit for implant 21 and a feldspar ceramic veneer on tooth 22.



11 | Intraoral try-in of the wax-up.



12 | First step: working model with replica of the Unit abutment.

retracted). A Unit abutment was connected to the implant for immediate loading, as shown on the intraoperative radiograph (Fig. 7).

The abutment was immediately loaded at 48 hours with a titanium cylinder and a provisional crown on top, seated at the interface of the Unit abutment (Fig. 8).

Following soft-tissue healing and removal of the sutures at two weeks, the gingiva had adapted nicely to the provisional (Fig. 9).

Three months later, when the implant had integrated and the soft tissue had matured, the site was prepared for the definitive crown and for the restoration of the adjacent teeth (which were discoloured following a previous endodontic treatment). A diagnostic wax-up was produced and tried intraorally. As shown in Figures 10 to 12, all-ceramic crowns were planned for sites 11 and 12

in addition to the cemented crown 21 on the Unit abutment, preserving the seal and attachment of the soft tissue achieved during the first stage of immediate loading. In addition, a veneer was made for tooth 12 to give it the same shade tone as the other anteriors as well as to reposition the gingival margin at a more aesthetic level for the smile line.

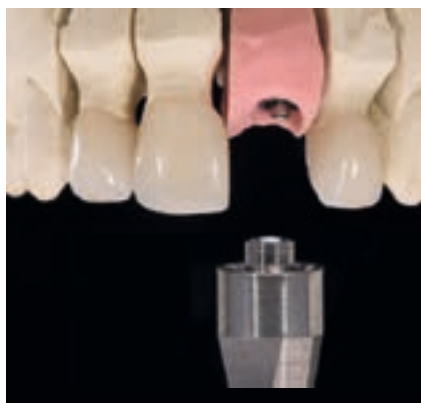Figures 13 to 17 show the next steps: An abutment was made from the cap inserted over the interface of the Unit abutment, followed by a ceramized custom post abutment (mesostructure) and finally a screw-retained crown. This design respects the connection of the hemidesmosomes at the gingival level created during the initial immediate-loading phase, which is maintained by this design without in any way compromising aesthetics in this highly sensitive region. Once the customized post abut-

ment and crown were ready, the restorations of the adjacent teeth were also completed (Fig. 18).

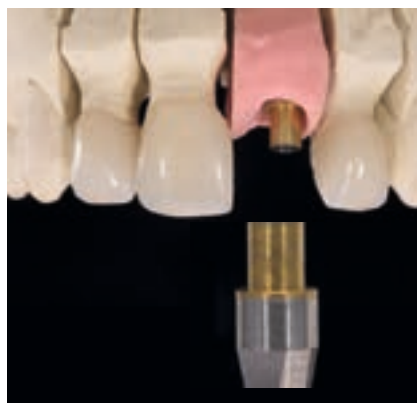At delivery, the crown was cemented and achieved excellent aesthetics (Fig. 19). The seal achieved and the BioBlock-shaping of the soft tissue that had been going on from the initial phase of implant insertion to the definitive insertion were successfully preserved. The orthopantomograph (Fig. 20) documents the treatment and the stable condition of the restoration and the bone.

Conclusion

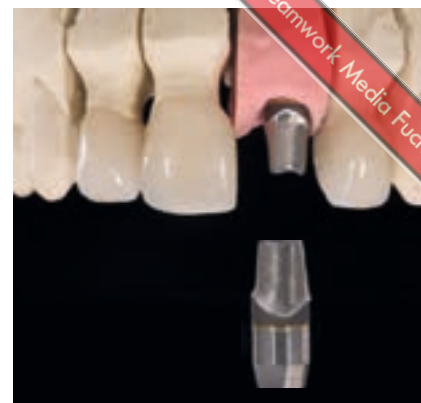The BioBlock concept ensures the “decent behaviour” of all the tissues in contact with its specifically designed surfaces, something that is even more critical in immediate-loading situations. The versatility provided by the abutment enables the restoration to be adapted to



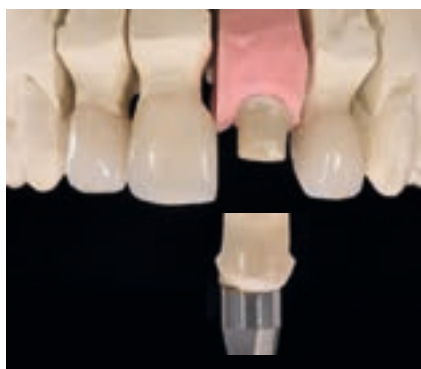13 | Interface of the Unit abutment on the laboratory replica.



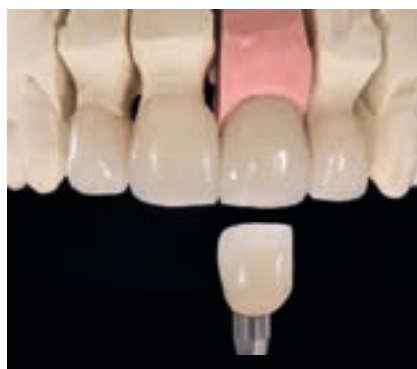14 | Abutment manufactured from the coping inserted over the interface of the Unit abutment, ready for ceramization.



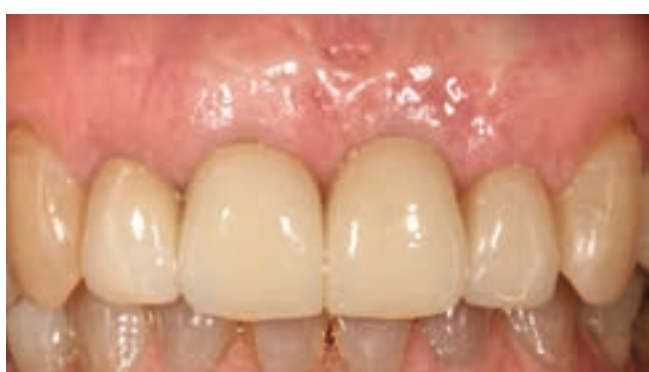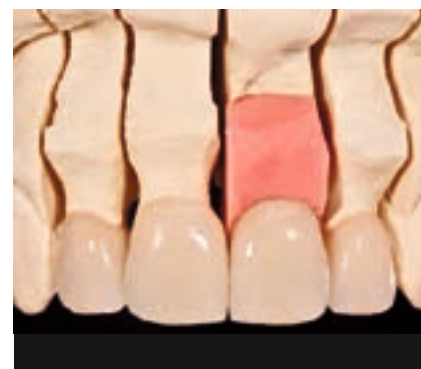15 | Ceramized post abutment showing the edges of the emergence profile that will be in ceramics for improved aesthetics. At this point, the post abutment is cemented on the interface to make it one solid component.



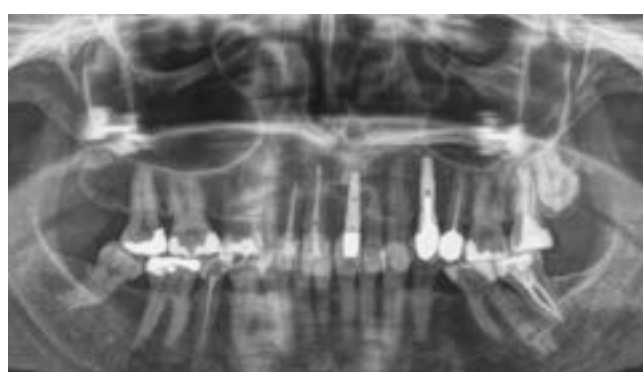
16 | Ceramic crown ready to be cemented onto the ceramized post abutment made on the interface of the Unit abutment.



17 and 18 | Completed restorations.



19 | The cemented restorations in situ.



20 | Final orthopantomograph.

the various steps of the process without compromising the interface between the implant and the bone.

The Unit abutment makes it easier to achieve these goals and provides prosthetic versatility, making it possible to perform various restorations that

guarantee good aesthetic results without disturbing the gingival seal achieved in the first phase of the procedure. ■

The references are available at www.teamwork-media.de/literatur

Contact address

Dr Eduardo Anitua
Eduardo Anitua Foundation
c/José María Cagigal 19
01007 Vitoria-Gasteiz
Spain
eduardoanitua@eduardoanitua.com